



## Versatility of the sural fasciocutaneous flap in coverage defects of the lower limb

Antonio Ríos-Luna<sup>a,b,\*</sup>, Manuel Villanueva-Martínez<sup>c</sup>,  
Homid Fahandezh-Saddi<sup>d</sup>, Fernando Villanueva-Lopez<sup>e</sup>,  
Miguel del Cerro-Gutiérrez<sup>c</sup>

<sup>a</sup> Department of Trauma and Orthopaedics Surgery, Hospital de Poniente, El Ejido, Almería, Spain

<sup>b</sup> NeuroScience and Health Science Department, University of Almería, Spain

<sup>c</sup> Department of Trauma and Orthopaedics Surgery, H.G.U. Gregorio Marañón, Madrid, Spain

<sup>d</sup> Department of Trauma and Orthopaedics Surgery, Hospital de Alcorcón, Madrid, Spain

<sup>e</sup> Department of Trauma and Orthopaedics Surgery, Hospital Alto Guadalquivir, Montilla, Córdoba, Spain

Accepted 10 July 2006

### KEYWORDS

Reverse-flow sural flap;  
Soft tissue defect

**Summary** We present in this work, our experience with the sural fasciocutaneous flap to treat coverage defects following a lower limb posttraumatic lesion. This paper is a review of these flaps carried out in different centres between 2000 and 2005. The series consists of 14 patients, 12 men and 2 women with an average age of 38 years (23–54) and with a medium follow-up time of 2 years (12–48 months). In all of the cases, aetiology was a lower limb injury or its complications, most frequently a distal tibial fracture (eight patients), followed by sequelae from Achilles tendon reconstruction (two patients), fracture of the calcaneus (two patients) and osteomyelitis of the distal tibia secondary to an open fracture (two patients). Associated risk factors in the patients for performing the flap were diabetes (one case) and cigarette smoking (four cases).

The technique is based on the use of a reverse-flow island sural flap with the superficial sural artery dependent on perforators of the peroneal arterial system. The anatomical structures which constitute the pedicle are the superficial and deep fascia, the sural nerve, short saphenous vein, superficial sural artery together with an islet of subcutaneous cellular tissue and skin.

The flap was viable in 13 of 14 patients. Only one flap failed in, a diabetic patient. No patient showed signs of infection. Slight venous congestion of the flap occurred in two cases. No further surgical intervention of the donor site was required. In two cases partial necrosis of the skin edges occurred which resolved satisfactorily with conservative treatment.

\* Corresponding author at: Orthopaedics and Traumatology Department, Hospital de Poniente, Avda de Almerimar s/n. 04700 El Ejido, Almería, Spain. Tel.: +34 950022528; fax: +34 950328731.

E-mail address: antonioriosluna@yahoo.es (A. Ríos-Luna).

The sural fasciocutaneous flap is useful for the treatment of complex injuries of the lower limbs and their complications. Its technical advantages are: easy dissection with preservation of more important vascular structures in the limb, complete coverage of the soft tissue defect in just one operation without the need of microsurgical anastomosis. All this results in a well vascularised cutaneous islet and thus a reliable flap.

© 2006 Elsevier Ltd. All rights reserved.

## Introduction

Coverage of soft tissue defects in the lower limbs is currently a more frequent procedure due to the increase incidence of "high energy" traumas which affect this location. The skilled orthopaedic surgeon should be capable of carrying out an integral treatment of these lesions which include not only open reduction and internal fixation of the fracture fragments but also the management of complications which may arise such as local skin necrosis. In 1987 Ferreira et al. presented the concept of fasciocutaneous flap of the distal pedicle based on the inframalleolar perforators.<sup>1,2</sup> In 1992, Masquelet et al. described the use of the neurocutaneous flap for reconstruction of soft tissue defects of the distal third of the leg.<sup>2</sup>

Among the main indications for a sural fasciocutaneous flap are soft tissue defects of the heel and the external or internal perimalleolar regions.

## Materials and methods

We present a retrospective review of the sural fasciocutaneous flaps (SFF) carried out in the four centres of work of the authors of this article by the Department of Trauma and Orthopaedics Surgery between 2000 and 2005. The series comprised 14 patients, 12 men and 2 women with an average age of 38 years (23–54) and with a medium follow-up of 2 years (12–48 months). The most frequent cause leading to a soft tissue defect in the lower limb in our series was a distal tibial fracture (eight cases) (Fig. 1A–D) followed by sequelae from Achilles tendon reconstruction (two cases) and a fracture of the calcaneus (two cases) (Fig. 2A–D) (Table 1). In the remaining patients (two cases) the aetiology was osteomyelitis of the distal third of the leg with a soft tissue defect of the perimalleolar area (Fig. 3A–C). One patient was diabetic and there were four smokers. All flaps but one (case 6) were suprafascial. In all

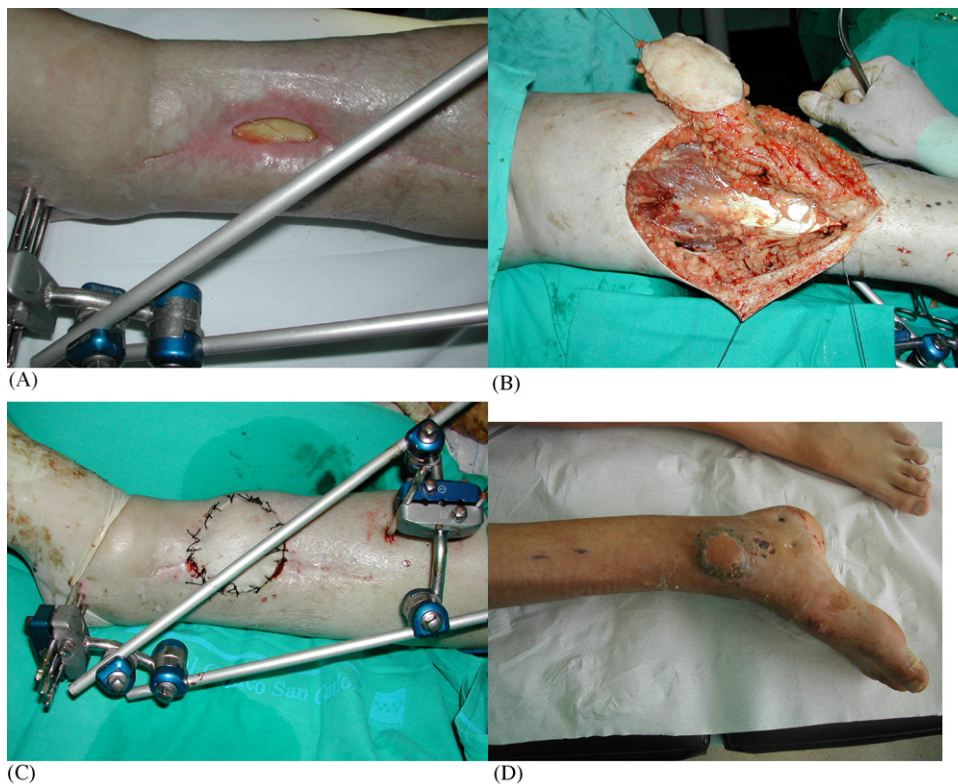
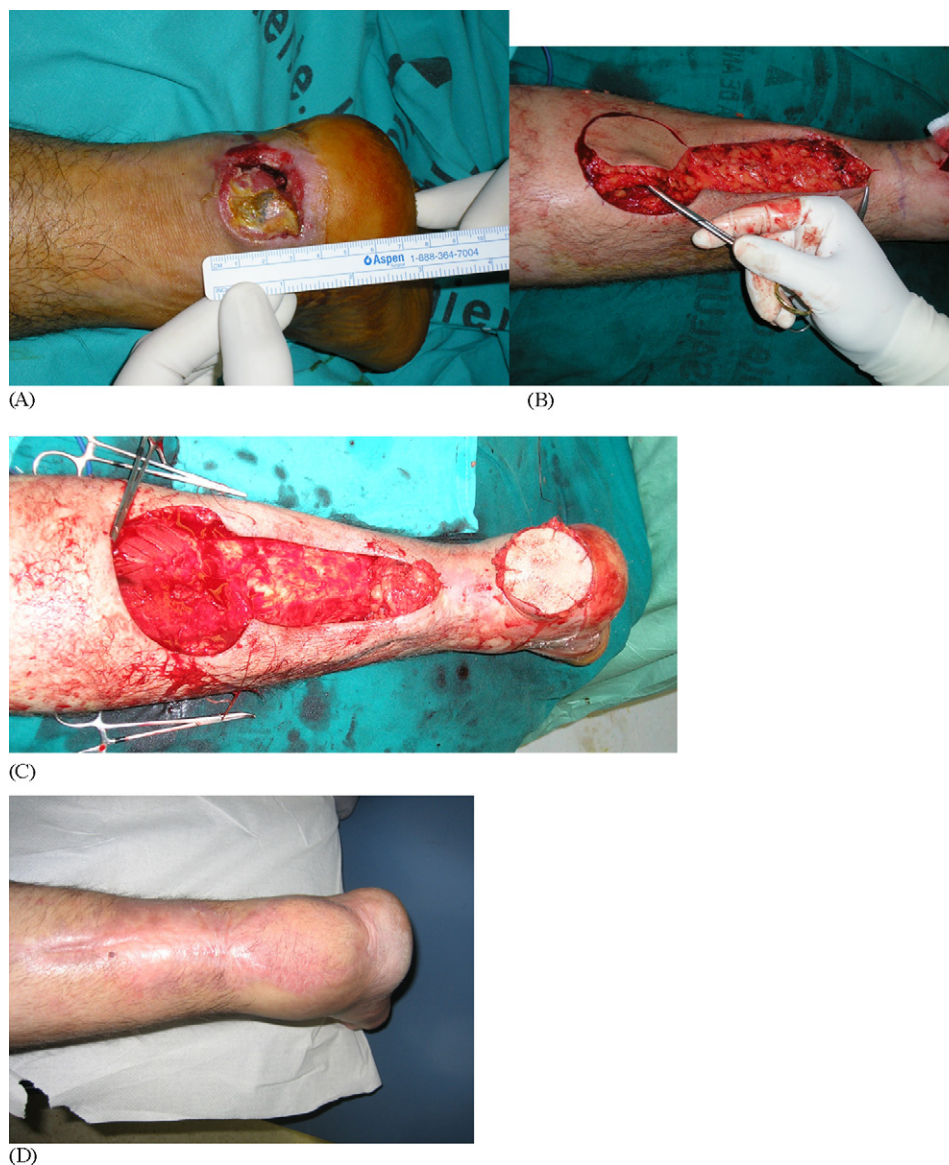
Figure 1 (A–D) Distal tibial fracture with external fixation. Final result.



**Figure 2** (A–D) Case 4. A calcaneus fracture and skin necrosis. Final result.

patients we used spinal anaesthesia and they were positioned prone. A tourniquet was placed in the proximal lower limb and exanguination achieved by elevation of the lower extremity; this facilitates the identification and dissection of the neurovascular structures in contrast with the use of the Esmarch bandage.

### Surgical technique

The sural fasciocutaneous flap (SFF) is made up of skin and subcutaneous fat, the superficial and deep fascia of the posterior part of the leg, sural nerve, the sural vein and the superficial sural artery. The graft is based specifically on the vascularisation that runs with the sural nerve. Flap irrigation is

accomplished by a distal reverse flow of the superficial sural artery dependent on perforators of the peroneal arterial system. There are numerous anastomoses between the peroneal artery and the vascular axis of the flap. The most distal is usually found at a distance of 4–5 cm above the tip of the peroneal malleolus and thus it is taken as the point where the pedicle pivots. The sural nerve is supplied by fasciocutaneous branches of the peroneal artery in the distal two thirds of the leg. The proximal third is supplied by the superficial sural artery.

Proximally, this flap cannot be delineated further than the junction of the heads of the gastrocnemius (Fig. 4A), as at this level the sural nerve and the artery are subfascial until they reach the popliteal fossa. However, it is possible to develop a subfascial viable flap, the so-called myofasciocutaneous flap

Table 1 List of patients

Case	Age/sex	Aetiology	Type of injury	Treatment	Defect	Size of the flap (cm)	Complications	Diabetes	Smoking
1	23 W	Trauma	Open ankle fracture	External fixation	Medial malleolus	6 × 5	No	No	Yes
2	25 W	Trauma	Ankle dislocation	Orif	Lateral malleolus	6 × 6	No	No	Yes
3	28 M	Trauma	Calcaneous fracture	Cast	Heel	6 × 5	No	No	Yes
4	40 M	Trauma	Calcaneous fracture	Orif	Heel	6 × 6	Bridge skin necrosis	No	No
5	28 M	Trauma	Ankle fracture	Orif	Medial malleolus	6 × 6	Venous congestion	No	No
6	53 M	—	Distal tibial osteomyelitis	—	Medial malleolus	6 × 5	Bridge skin necrosis	No	No
7	47 M	Sport injury	Achilles rupture	Suture	Achilles	5 × 5	No	No	No
8	54 M	Sport injury	Achilles rupture	Suture	Achilles	6 × 4	No	No	No
9	46 M	Trauma	Distal tibial fracture	External fixation	Medial malleolus	5 × 4	No	No	No
10	39 M	Trauma	Ankle fracture dislocation	Orif	Medial malleolus	6 × 6	Venous congestion	No	No
11	48 M	Trauma	Distal tibial fracture	Orif	Medial malleolus	5 × 5	No	Yes	No
12	21 M	Trauma	Open tibial fracture	External fixation	Medial malleolus	6 × 4	No	No	No
13	38 M	Trauma	Distal tibial osteomyelitis	Curettage	Medial malleolus	5 × 5	No	No	Yes
14	58 M	Trauma	Ankle fracture	Orif	Medial malleolus	6 × 6	No	No	No

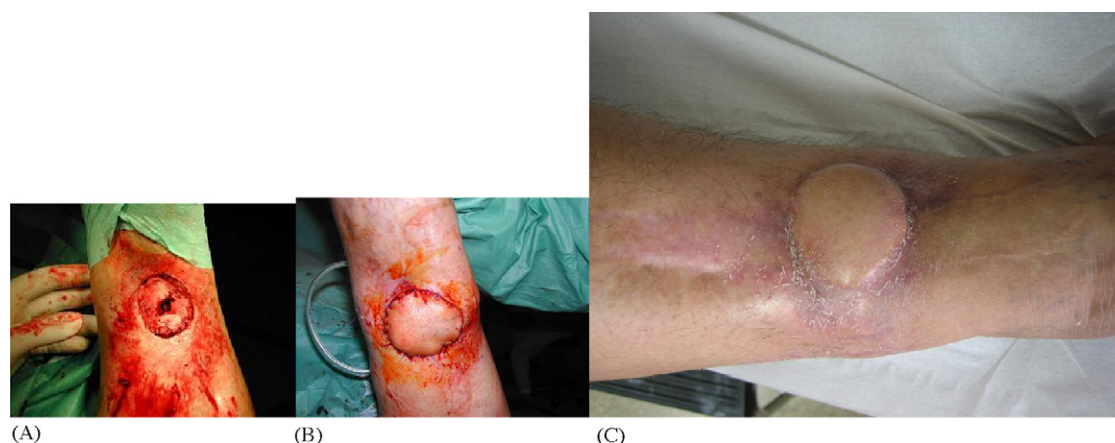such as in case 6 of our series where it was necessary to cover a deeper soft tissue defect, for which we incorporated part of the gastrocnemius muscular mass.

We have always initially drawn the pivotal point of the pedicle 4–5 cm from the lateral malleolar tip. We outline the expected trajectory of the sural nerve, artery and vein in the posterior aspect of the calf. Then we measured the defect to cover and based on its dimensions, we draw the skin islet to be transferred in the form of a paddle centred over the depicted neurovascular sural bundle. A broad dissection is carried out to incorporate the deep fascia, dividing the sural nerve proximally and ligating the artery and the vein (Fig. 4B). The entire flap is elevated and dissected from proximal to distal. Stay stitches were placed between the skin and subcutaneous fascia to prevent sliding of both layers that may damage the perforators which constitute the basis of this flap. At this stage careful diathermy of the bleeding perforators in the lateral margins of the flap is mandatory. In this way, the gastrocnemius musculature is left exposed. Dissection of the graft has to reach the distal limit which we marked, 4–5 cm proximal to the lateral malleolus. The width of the carrier pedicle is 3–4 cm. A subcutaneous tunnel is created and the flap is then transposed to the area of the defect we wish to cover, by carefully rotating the flap over its pedicle up to 180° (Fig. 4C).

The donor site is closed with interrupted sutures if the islet skin flap dissected is no wider than 5–6 cm. Otherwise a free skin graft may be used to cover the defect created. At the end of this procedure the tourniquet is deflated and adequate circulation of the flap verified. Numerous punctures of the flap, using a 25 G needle, are made to allow bleeding, thus minimising hyperaemia and venous congestion. A drain is left under the rotated flap to minimise the likelihood of haematoma formation. The limb is dressed with cotton and elastic bandages.

## Results

The flap yielded a satisfactory cover of the defect in 13 of 14 cases. The flap failed and necrosed in the only diabetic patient in this series. This happened due to microvascular angiopathy and it might have been prevented by using a fasciomusculocutaneous – usually indicated to cover much greater and deeper defects – since the skin is accompanied by transferring healthy muscle from the gastrocnemius mass. When we removed the necrosed graft we found a healthy bed of soft tissue which allowed a secondary intention closure. In two cases skin bridge necrosis



**Figure 3** (A–C) Distal tibial osteomyelitis and fasciomusculocutaneous graft. Final result.

occurred in the area of the flap tunnelling that resolved satisfactorily without affecting the progress of the graft and with no significant consequences. Infection was not observed in any of the cases and slight venous congestion “of the flap” occurred in two patients. The donor area did not require further surgery in any of the patients in this series. The average surgery time was 70 min (50–90). The average size of the flap taken was 5 cm × 5 cm.

## Discussion

There is a large variety of muscular or pedicled flaps for reconstruction of lower limb soft tissue defects. The use of these techniques is not common among orthopaedic surgeons due to the lack of familiarity with them and the potential for flap failure and problems derived from morbidity of the donor site.

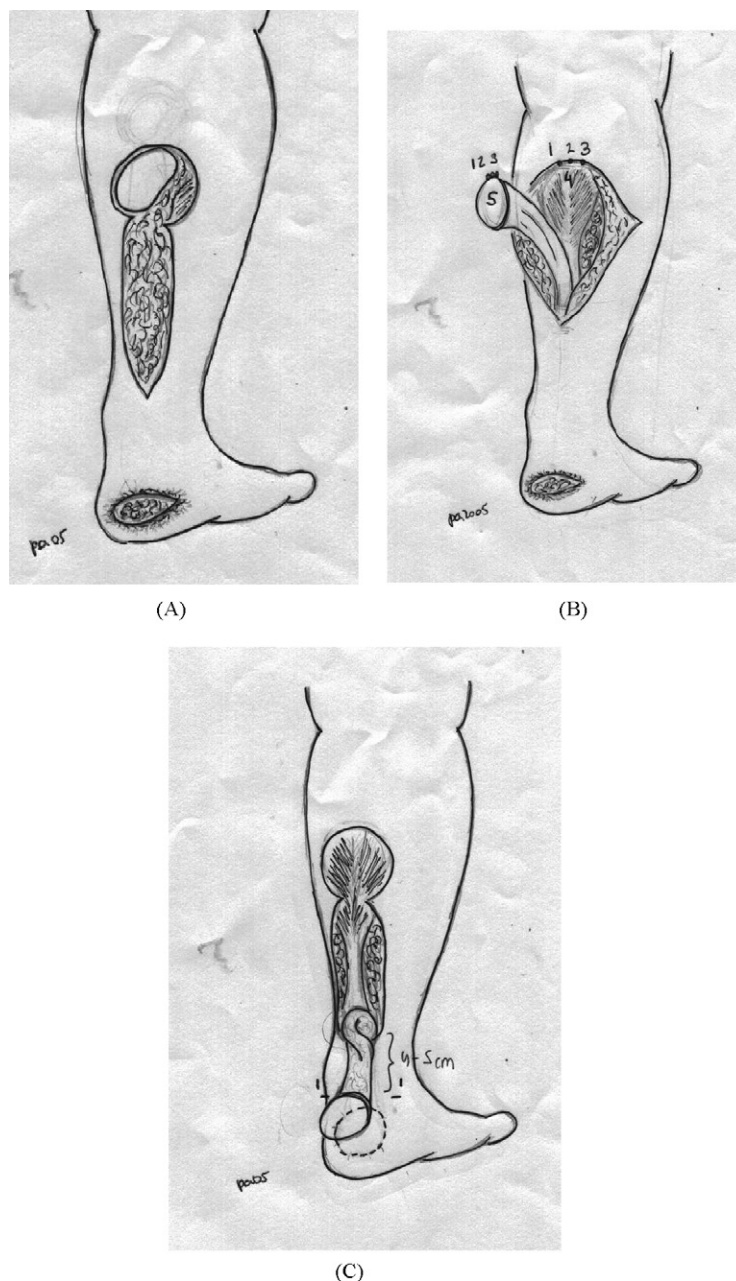
Free flaps, lateral supramalleolar skin flap, posterior tibial perforator flap are the main alternative to sural flaps. Free flap reconstruction of defects requires lengthy and costly hospitalisation, microsurgical training and experience, special instruments and a two-team approach. The long operative time and functional donor-site morbidity are major disadvantages of this method. Good planning and microsurgical experience are the most important factors for successful results. Free flaps are advised for extensive skin defects or in cases where poor distal vascularity of the leg or local trauma precludes the reliability of a distally based fasciocutaneous flap.<sup>1–10</sup>

A lateral supramalleolar skin flap offers a range of coverage similar to that of the sural flap but the dissection is more difficult than for a sural flap and offers no advantages; the area of anaesthesia in sural flaps is smaller than after transecting the superficial peroneal nerve. Theoretically, the sural

flap does not cover as distally as the supramalleolar flap but some authors stated that the distally based sural flap is more reliable than the lateral supramalleolar flap, especially regarding the venous congestion and have shown the usefulness of the sural flap for weight bearing areas even when revascularisation is not performed; a lateral supramalleolar skin flap is not recommended for coverage in this areas. The global proportion of failures is almost four times as great for the supramalleolar skin flap.<sup>14</sup>

The posterior tibial perforator flap is another option.<sup>4</sup> It is a very reliable flap and indicated in lower limb defects, especially in reconstruction of chronic Achilles tendon defects. A more difficult dissection, a larger learning curve are the main disadvantages. A medial distal septocutaneous flap,<sup>7</sup> based on the intermuscular posterior tibial perforators is an alternative.

The advantages of the sural flap compared to other covering methods are the simplicity of the design and dissection of the pedicle flap that can be carried out with a loup magnification and without the need for microsurgical instrumentation or anastomosis, the preservation of the principle vascularisation of the lower limb and the need for only one operation. The sural pedicled flap constitutes a well vascularised cutaneous islet and reliable flap offering the possibility of covering a broad range of areas with cutaneous defects in the distal tibia, heel and “up to the” rear foot. The sural flap has been used in patients with diabetes mellitus and recurrent plantar ulcers that require a major muscular coverage, even though the only diabetic patient in our series failed. We explain that failure with the presence of severe microangiopathy and because we did not use a fasciomusculocutaneous flap which enables coverage of much greater and deeper defects since the skin is accompanied by transferring healthy muscle from the gastrocnemius mass.



**Figure 4** (A) This flap cannot be delineated further than the junction of the heads of the gastrocnemius. (B) A broad dissection is carried out to incorporate the deep fascia, cutting the sural nerve (1) proximally and ligating the artery (2) and the vein (3). (C) A subcutaneous tunnel is created and the flap can then be transposed to the area of the defect we wish to cover, being able to rotate the flap over its pedicle carefully up to 180°.

The sural flap can be especially useful in cases of injuries with serious compromise to the circulation of the major arteries of the lower limb as long as the peroneal artery is intact or when a microsurgical procedure is contraindicated. One of the few disadvantages of this flap is that by sacrificing the sural nerve, an inevitable anaesthesia area appears over the lateral aspect of foot which usually is well tolerated by the patient. The survival index of the flap exceeds 90%. It can be used in an emergency

situation and it does not expose it to the failure of the flap.<sup>1</sup>

Masquelet et al.<sup>12</sup> were the first to describe the vascularisation of the skin in the lower limb and the arteries which follow the trajectory of the peripheral nerves. The sural nerve comes down the leg in close relationship with the short saphenous vein. This nerve is supplied by the superficial sural artery in the proximal third of the calf and by fasciocutaneous branches arising from the peroneal artery in

the distal half of the leg along the suprafascial course of the sural nerve. This sural artery anastomoses with the peroneal artery by means of 3–5 fasciocutaneous perforators which ensure adequate inverse irrigation of the flap. The peroneal artery supplies the sural nerve and venous anastomoses circulate along this artery to ensure venous return. Several authors have demonstrated that the main anastomosis of this arterial network is located 5 cm proximal to the peroneal malleolar point.<sup>1–3,5–7,9,10</sup> Other surgeons do not include the sural nerve in the flap based on the existence of a perforated branch of the peroneal artery which by itself is capable of irrigating the graft without the need to transfer the accompanying nerve.<sup>1,2,5,8,15</sup>

Some authors perform a Doppler test prior to the intervention that confirms the integrity of the peroneal artery, its anastomosis with the fasciocutaneous branches and the precise localisation of the pivot point on which the flap should rotate.<sup>6,9,13</sup> Other surgeons only do a Doppler examination of the lower limb when there is reasonable doubt as to the normality of the peroneal artery which is the anatomical basis of this graft.<sup>1–3,6,7</sup> We have not carried out a Doppler test in any of our patients because there was no lesion to suspect the presence of abnormalities in the vascular tree mentioned above.

With respect to the size of the flap, the largest dimension documented in the literature is 17 cm × 16 cm, but the complication rate increases accordingly with the graft size. With enlarged flaps, the larger pedicle may be compressed more easily once it is tunnelled and post-operative swelling increases which may augment venous congestion of the flap with the risk that this involves<sup>11,12,14–17</sup> and a greater possibility of suffering partial necrosis of the skin bridge under which the graft is tunnelled. Other authors do not tunnel the flap under the skin due to fear of compression of the fatty pedicle against the skin especially in the postoperative phase when more swelling develops.<sup>5</sup> The donor area morbidity increases in relation to the size of the flap dissected being sometimes necessary to cover the defect created with a large free skin graft. In our group, the average size was 5 cm × 5 cm.

Other authors use these same anatomical principles by creating the fasciomuscular grafts and the subfascial course of the nerve<sup>5</sup> by creating a fasciomusculocutaneous graft making use of the proximal subfascial course of the sural nerve. The basis is always the sural nerve but a variant is added, the inclusion of a fragment of the gastrocnemius in the flap that depends on perforating arteries that run from the sural nerve to the gastrocnemius musculature. There is no risk of necrosis of this

musculature since it is vascularised inversely like the original sural flap. This method provides adequate coverage to greater and deeper defects since the skin is accompanied by transferring healthy muscle from the gastrocnemius mass. Moreover, the literature even shows a series of osteomyelitis cases treated with this flap with excellent results<sup>5</sup> as we did in case 6.

In some hospitals there may be no plastic surgeon available on a daily or regular basis. Although some of the converging techniques or flaps may require the use of microsurgical instrumentation and skills with a special training, this should not be the case with the sural fasciocutaneous flap. We believe that the fasciocutaneous sural flap is a simple and quick technique that can be easily reproduced with a low rate of complications.

The sural flap constitutes a reliable and versatile technique that should form part of the therapeutic arsenal of all the orthopaedic surgeons, facilitating the integral treatment of complex lower limb injuries with exposed defects.

## Acknowledgement

We thank Francisco Arias-Lotto for the drawings illustrating the technique.

## References

1. Ayyappan T, Chadha A. Supersural neurofasciocutaneous flaps in acute trauma heels reconstruction. *Plast Reconstruct Surg* 2002;109:2307–13.
2. Baumeister SP, Spierer R, Erdman R, et al. A realistic complication analysis of 70 sural artery flaps in a multimorbid patients group. *Plast Reconstruct Surg* 2003;112:129–40.
3. Benito-Ruiz J, Yoon T, Guisantes-Pintos E, et al. Reconstruction of soft tissue defects of the heel with local fasciocutaneous flaps. *Ann Plast Surg* 2004;52:380–4.
4. Cavadas PC, Landin L. Reconstruction of chronic Achilles tendon defects with posterior tibial perforator flap and soleus tendon graft: clinical series. *Plast Reconstruct Surg* 2006;117:266–71.
5. Chen SL, Chen TM, Chou TD, et al. Distally based sural fasciomusculocutaneous flap for chronic calcaneal osteomyelitis in diabetic patients. *Ann Plast Surg* 2005;54:44–8.
6. Colen B. A realistic complication analysis of 70 sural artery flaps in a multimorbid patient group. *Plast Reconstruct Surg* 2003;112:140–1.
7. Costa Ferreira A, Reis J, Amarante J. Reconstruction of soft tissue defects of the heel with local fasciocutaneous flaps. *Ann Plast Surg* 2005;54:580–1.
8. Erdman D, Gottlieb N, Humphrey S, et al. Sural flap delay procedure: a preliminary report. *Ann Plast Surg* 2005;54:562–5.
9. Figueiredo M, Da Costa PR, Okawa RY. Reverse flow island sural flap. *Plast Reconstruct Surg* 2002;109:583–91.

10. Jeng SF, Wei FC. Distally based sural island flap for foot and ankle reconstruction. *Plast Reconstruct Surg* 1997;99:744–50.
11. Le Four B, Caye N, Pannier M. Distally based sural fasciomuscular flap: anatomic study and application filling leg or foot defects. *Plast Reconstr Surg* 2001;107:67–72.
12. Masquelet A, Gilbert A. Distally based sural artery neurocutaneous flap. In: En Masquelet A, Gilbert A, editors. *An atlas of flaps of the musculoskeletal system*. Londres: Martin Dunitz; 2001. p. 186–7.
13. Ogun TC, Arazi M, Kutlu A. An easy and versatile method of coverage for distal tibial soft tissue defect. *J Trauma* 2001;50:53–9.
14. Price MF, Capizzi PJ, Watterson PA, Lettieri S. Reverse sural artery flap: caveats for success. *Ann Plast Surg* 2002;48:496–504.
15. Touam C, Rostoucher P, Bathia A, Oberlin C. Comparative study of two series of distally based fasciocutaneous flap for coverage of the lower one-fourth of the leg, the ankle and the foot. *Plast Reconstr Surg* 2001;107:383–92.
16. Tu YK, Veng S, Yeh WL, Wang KC. Reconstruction of the ankle and heel defects by a modified wide-base reverse sural flap. *J Trauma* 1999;47:82–8.
17. Yildrin S, Akan M, Akoz T. Soft Tissue reconstruction of the foot with distally based neurocutaneous flap in diabetics patients. *Ann Plast Surg* 2002;48:248–54.